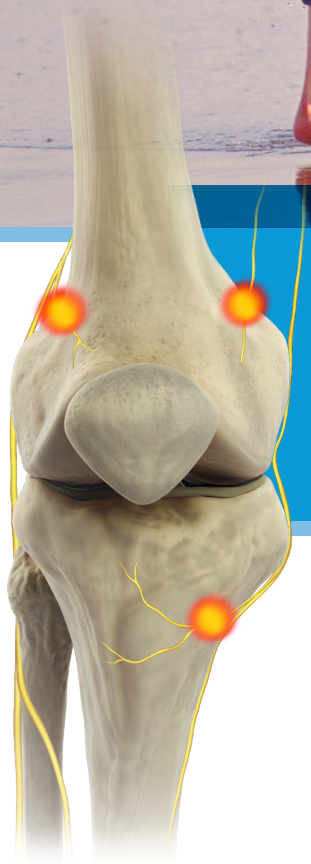

Genicular RF

Non-Surgical Treatment of Chronic Knee Pain

COSMAN

The Leader in RF Medicine Since 1952

Genicular RF Treatment of Chronic Knee Pain

A Simple Treatment for a Widespread Problem

Chronic knee osteoarthritis (OA) is a painful disorder common among adults of advanced age.[1] Radiofrequency (RF) is a non-surgical and non-narcotic treatment option for those who are not candidates for invasive surgery.[1,2,3,4] Cosman devices are indicated for use in RF heat lesioning of peripheral nerve tissue for the treatment of pain.

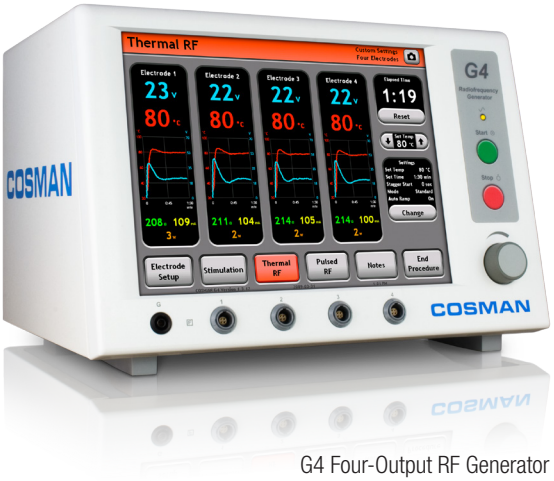

G4 Four-Output RF Generator

Treat Multiple Nerves at the Same Time

Treating multiple nerves at the same time with conventional RF electrodes saves time and reduces costs. Cosman's G4 generator can operate up to four electrodes using thermal or pulsed RF, and monopolar or bipolar RF.

Larger Lesions than Cooled RF

A physician can adjust ablation size by selection of cannula size and generator settings.[5] Conventional monopolar and bipolar radiofrequency applied for 3 minutes can create larger ablation zones than cooled RF.*

Monopolar RF

Cooled	16ga/6mm	18ga/10mm
60/77°C	85°C	90°C

W = 9.9	W = 10.2	W = 9.9 mm
L = 8.9	L = 11.3	L = 13.4 mm

Bipolar RF

10mm tips	90°C	s=12mm
20ga		18ga

W x L

W x D

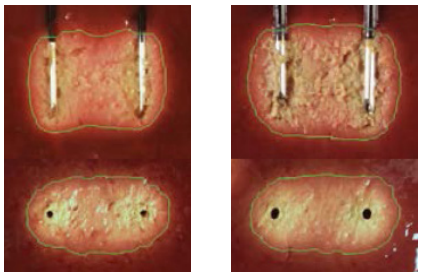

W = 18.1	W = 18.7 mm
L = 10.8	L = 12.9 mm
D = 9.2	D = 9.4 mm

Studies on Conventional RF for Chronic Knee Pain

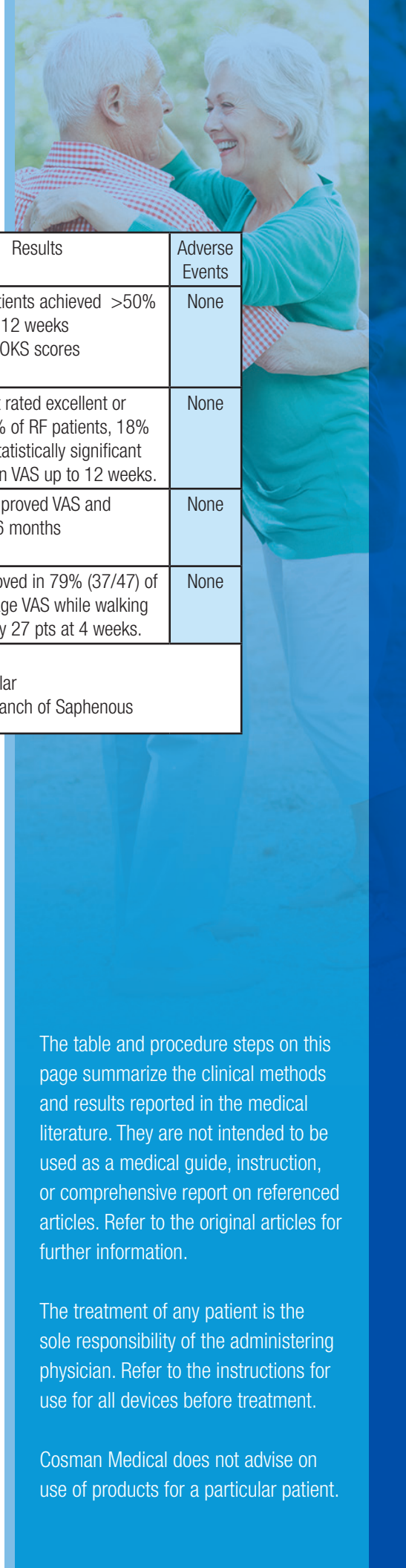

Study	Number of Patients: Treatment Details	Generator Settings	Cannula Configuration	Results	Adverse Events
Choi et al[1]	38 (19 RF, 19 control): RCT of thermal RF at the superior lateral, superior medial, and inferior medial genicular nerves.	70°C for 90 seconds	10cm, 22 gauge, 10mm active tip	P: 10/17 patients achieved >50% reduction at 12 weeks F: Improved OKS scores	None
Ikeuchi et al[2]	35 (18 RF, 17 control): Open-label, controlled, non-randomized study of thermal RF at the MR and IPBS nerves.	70°C for 90 seconds	5cm, 22 gauge, 5mm active tip	P: Treatment rated excellent or good by 44% of RF patients, 18% of control. Statistically significant differences in VAS up to 12 weeks.	None
Akbas et al[3]	115: Prospective study of PRF of the saphenous nerve.	≤42°C, 40V, 2Hz, 20ms for 480 seconds	5/10cm, 22 gauge, 5mm active tip	P, F: 84% improved VAS and WOMAC at 6 months	None
Djibilian et al[4]	25 (47 knees): Prospective study of ultrasound-guided PRF of the sciatic nerve.	45V for 480 seconds	10cm, 23 gauge, 5mm active tip injection electrode	P: VAS improved in 79% (37/47) of cases. Average VAS while walking decreased by 27 pts at 4 weeks.	None

Glossary:
P – Pain reduction
F – Functional improvement
RF – Radiofrequency
PRF – Pulsed RF
MR – Medial Retinacular
IPBS – Infrapatellar Branch of Saphenous

Conventional RF Knee Procedure[1]

1. The patient is placed in supine position on an x-ray fluoroscopy table with a pillow under the popliteal fossa for comfort. The surgical site is prepared for aseptic technique, and the skin is numbed at the cannula insertion sites using local anesthetic.
2. Aseptic technique and fluoroscopic guidance are used throughout cannula placement and during treatment.
3. A true AP fluoroscopic view is obtained that shows an open tibiofemoral joint with equal interspaces on both sides.
4. An RF cannula with a 10cm shaft and 10mm active tip is advanced using a “tunnel technique” until bone contact is made at the area connecting the femur shaft and lateral epicondyle. This is repeated at the medial femur and medial tibia.
5. With the patient awake, each cannula is positioned near its target nerve by requiring a response to Sensory stimulation (50Hz, 1msec) at less than 0.6 Volts. To prevent inactivation of motor nerves, an absence of fasciculations in the lower extremity is required when Motor stimulation (2Hz, 1msec) is applied to each cannula at 2 Volts.
6. Lidocaine (2mL of 2%) is injected through each cannula.
7. A temperature-sensing RF electrode is inserted into each cannula, and RF is applied for 90 seconds using set temperature of 70°C. Three lesions are created in total, one at each genicular nerve (see front cover). The patient is continuously monitored for signs of discomfort.
8. Following RF procedure, the cannula is withdrawn and a bandage is placed over the skin insertion site.

The table and procedure steps on this page summarize the clinical methods and results reported in the medical literature. They are not intended to be used as a medical guide, instruction, or comprehensive report on referenced articles. Refer to the original articles for further information.

The treatment of any patient is the sole responsibility of the administering physician. Refer to the instructions for use for all devices before treatment.

Cosman Medical does not advise on use of products for a particular patient.

Cosman's Specialized Treatment Options

Unified Electrode/Cannula

The Cosman Unified (CU) electrode replaces a separate electrode and cannula with a single disposable probe. This all-in-one electrode can be used for insertion, injection, stimulation, and temperature-controlled RF in the knee and in other pain management applications.

- Reduce procedure steps
- Reduce inventory
- Avoid sterilization logistics and costs
- Echogenic tip available

Unified Electrode

1. Place the CU RF electrode
2. Stimulate
3. Inject through the flexible tubing
4. Deliver RF

Electrode and Cannula

1. Place the RF cannula
2. Remove the cannula's stylet and replace with the RF electrode
3. Stimulate
4. Remove the electrode for injection
5. Inject directly into the cannula's hub
6. Place the RF electrode in the cannula
7. Deliver RF

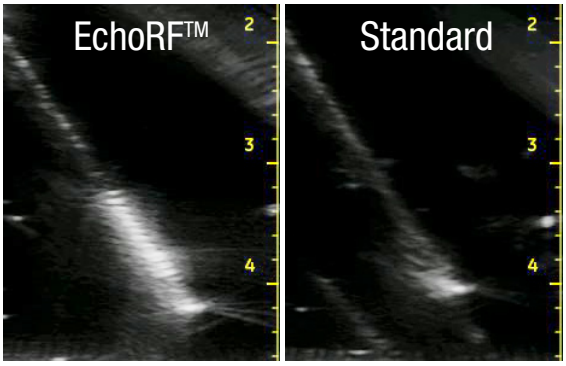

Gel media, GE® Venue™40 and 12L-SC ultrasound transducer.

Echogenic Cannula

Ultrasound imaging can be used to target nerves innervating the knee.[4] It allows for direct imaging of nerves relative to the RF cannula. Cosman EchoRF™ cannula improve tip visibility compared with standard cannula.

References

1. Choi et al. Radiofrequency treatment relieves chronic knee osteoarthritis pain: a double-blinded randomized controlled trial. Pain 2011;152:481-7
2. Ikeuchi et al. Percutaneous radiofrequency treatment for refractory anteromedial pain of osteoarthritic knees. Pain Med. 2011;12(4):546-51
3. Akbas et al. Efficacy of pulsed radiofrequency treatment on the saphenous nerve in patients with chronic knee pain. JBMR 2011;24:77-82
4. Djibilian et al. Ultrasound-guided sciatic nerve pulsed radiofrequency for chronic knee pain treatment: a novel approach. J Anesth. 2013;26(6):935-8
5. Cosman et al. Factors That Affect Radiofrequency Heat Lesion Size. Pain Med. 2014;15(12):2020-36
6. Cohen et al. Randomized placebo-controlled study evaluating lateral branch radiofrequency denervation for sacroiliac joint pain. Anesthesiology 2008;109:279-88

* Average lesion size is assessed by color change in fresh bovine liver ex vivo. Ex vivo lesions may differ from clinical lesions.[5] Compared to cooled RF configuration for SIJ devernation.[6]

COSMAN
www.cosmanmedical.com

Tel: +1 781 272 6561
Fax: +1 781 272 6563
info@cosmanmedical.com

Cosman Medical, Inc.
76 Cambridge Street
Burlington, MA USA 01803

SPI12894 Rev A 20150714