

A Novel Minimally Invasive Wireless Technology for Neuromodulation via Percutaneous Lateral Femoral Cutaneous Nerve Stimulation for Meralgia Paresthetica: A Case Report with 3-Month Follow-Up

Stefan Stockli¹, Elissa R. Ettinger² and Niek E. Vanquathem BA²

¹Schmerztherapie Emmental, Burgdorf, Switzerland.

²Stimwave Technologies LLC, Pompano Beach, Florida, USA.

*Correspondence:

Niek E. Vanquathem, Stimwave Technologies LLC, Pompano Beach, Florida, USA, Tel: 0032 492 69 22 23; Fax: (800) 965-5134; E-mail: niek@freedomneuro.com.

Received: 26 February 2018; Accepted: 18 March 2018

Citation: Stefan Stockli, Elissa R. Ettinger, Niek E. Vanquathem. A Novel Minimally Invasive Wireless Technology for Neuromodulation via Percutaneous Lateral Femoral Cutaneous Nerve Stimulation for Meralgia Paresthetica: A Case Report with 3-Month Follow-Up. J Clin Anesth Res. 2018; 2(1): 1-4.

ABSTRACT

Background: Peripheral nerve stimulation (PNS) of the lateral femoral cutaneous nerve provides control of burning pain and severe allodynia in the anterolateral thigh at the right side.

Objective: To assess analgesic effects of a minimally invasive wireless neuromodulation in the treatment of chronic pain due to Meralgia Paresthetica.

Case Summary: A patient presented with burning pain and severe allodynia in the right anterolateral thigh, and was subsequently diagnosed with Meralgia Paresthetica. The patient's problems began with arthroscopy of the knee for cruciate ligament repair and several debridements following that. Thereafter, he developed infection, empyema, and life-threatening necrotizing fasciitis. In 2015, he had adhesiolysis of the femoral cutaneous nerve by a hand surgeon resulting in one year relief of pain, and thereafter, recurring pain. Other previous therapies attempted include: cryoablation of the femoral cutaneous nerve; repeated ultrasound-guided femoral cutaneous nerve blocks; physiotherapy; and medications including tramadol, paracetamol, acetaminophen, tapentadol, pregabalin, lidocaine patch, and trimipramin. Patient was deemed a suitable candidate for a minimally invasive neuromodulation procedure. One subcutaneous electrode was inserted approximately 20 cm below the groin in the anterior thigh on the right side, and placed on the lateral femoral cutaneous nerve.

Results: The procedure was uneventful, and pain scores (NRS) reduced from a 10 out of 10 before stimulation to a 0 while applying stimulation at 3-months follow-up.

Conclusions: Subcutaneous placement of electrodes with a minimally invasive technique and wireless technology was safe and effective. Significant improvements in pain relief ensued at the three-month follow-up with no adverse events.

Keywords

Meralgia Paresthetica, Neuropathy, Lateral femoral cutaneous nerve, Wireless, Neuromodulation, Minimally invasive, Peripheral nerve stimulation.

Introduction

Currently, one of the most common problems that lead patients to seek medical attention, and thus a prevalent cause for public

concern, is chronic, refractory pain [1,2]. Challenging to both the patient and the clinician, refractory pain following the use of medications and physiotherapy, often leads to invasive treatments such as nerve blocks, epidural injections, nerve cryoablation, or adhesiolysis of the nerves. When none of these treatments work, the next step in the paradigm is spinal cord stimulation (SCS) that may or may not relieve the entire area of pain distribution [3]. At this point, a more valuable alternative or addition to the

neuromodulation protocol is PNS.

PNS is a viable option in those cases in which SCS is unsuitable. This treatment, which includes placement of electrodes underneath the skin to deliver electric energy to the target nerves or nerve endings in the area of pain distribution, has been reported to produce sustained paresthesia in difficult to treat regions of the body. Even though PNS is a relatively new strategy of neuromodulation, literature supports its effective analgesic property [4-9].

When SCS electrodes are placed in the spinal epidural space, they stimulate the large myelinated fibers of the dorsal column. PNS, however, is positioned in the area of pain distribution and targets the cutaneous afferents leading to the spinal cord [10]. In PNS, the stimulators activate the large afferents and modulate the A-delta and C-fibers, possibly producing an anti-inflammatory and membrane depolarizing effect on the dermatomal nerve fibers [11]. This technique's efficacy was reported in the Austrian retrospective study from 111 Austrian patients [6].

Off-label use of SCS components is commonly used with PNS, which often lead to technical shortcomings. Failed SCS and PNS reasons include device alignment, stimulation parameters, and most importantly, implant complications such as lead migration, fracture, and malpositioning [12-14]. Serious complications due to tunneling towards the IPG include infections and IPG pocket pain [14].

We report a novel, minimally invasive wireless device, the Freedom stimulator, CE mark approved for PNS that is specifically designed to mitigate the complications of conventional devices used with PNS.

Case Report

The patient presented with the chief complaint of burning pain and severe allodynia in the anterolateral thigh at the right side, resulting in the diagnosis of Meralgia Paresthetica. Previous surgery and other methods of treatment included arthroscopy of the knee and repair of the cruciate ligament with severe complications thereafter with infection, empyema, and necrotizing fasciitis. Following that, the patient underwent adhesiolysis of the femoral cutaneous nerve by a hand surgeon in 2015, which was accompanied by a year of analgesia. Nevertheless, the pain recurred. Other therapies tried before the patient presented with allodynia include cryoablation twice of the femoral cutaneous nerve, repeated ultrasound-guided femoral cutaneous nerve blocks, and physiotherapy. The medications tramadol, paracetamol, acetaminophen, tapentadol, lidocaine patch, and trimipramin were also tried. Because the patient's pain persisted, he was deemed a viable candidate for the wireless peripheral nerve stimulation of the right-sided femoral cutaneous nerve.

Methodology

After informed consent, the patient was taken up for placement of subcutaneous placement of electrodes for neuromodulation.

Device description

One Freedom stimulator system (Stimwave Technologies, Pompano Beach, FL, USA) was implanted in the patient. Containing four contacts (3 mm in diameter with 4 mm spacing), the stimulator utilizes an implantable electrode array, microprocessor receiver, and antenna embedded within the electrode wire (Figure 1) that couples to an external transmitting antenna and pulse generator. The implanted stimulator is 100% passive (i.e., no power source). The external transmitter is worn over a single layer of clothing and is used to transmit power to the stimulator. The antenna and transmitter are worn with a brace and positioned over the location of the receiver. Finally, the external pulse generator is programmed by the medical professional to send the desired stimulation parameters through a direct coupling RF transmitting antenna to the electrode receiver, thereby wirelessly transferring stimulation commands and power to the implanted stimulator. 915 MHz is the radiofrequency energy the system uses to transfer power and the selected parameters to the implanted stimulator. The energy emitted from the antenna is relatively low because the implanted stimulator and power source are coupled at such a short distance. Wavelengths and product specifications have been designed to decrease the risks related to the wireless transmission of energy (REF) and reliably transfer the medical professional's desired stimulation parameters. The stimulation parameter spectrum available for clinical use and evaluation include:

- Amplitude: 1-24 mA;
- Pulse Width: 1-1000 microSec;
- Frequency: 1-20,000 Hz




Figure 1: Neuro-stimulator electrode, MRI compatible, for both 1.5 and 3 Tesla.

Surgical Procedure

Under strict aseptic conditions, the entry point for the electrode's placement was approximately 20 cm below the groin in the right anterior thigh, and the electrode was placed on the lateral femoral cutaneous nerve (Figure 2). It was subsequently anchored through the lead and to the skin in order to prevent distortion, bending, or painful motorstimulation, which could occur if secured to the fascia.

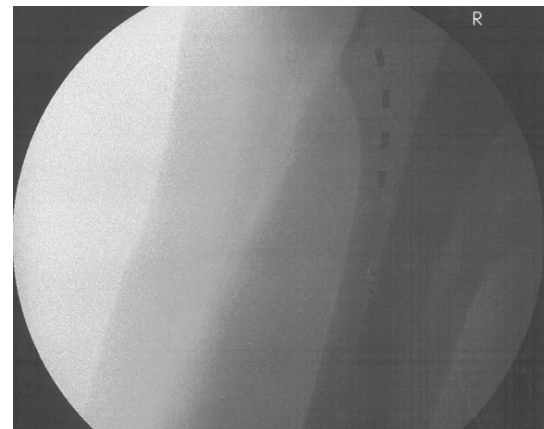

Figure 2: X-ray of device placement.

Stimulation protocol

A stimulation regimen was applied for the trial time and through the 3-month follow-up. Stimulation parameters were set at a pulse width of 300 microseconds and frequency of 60 Hz. Intensity of the device was set at 0.5 mA. The external transmitter was worn on the upper right leg.

Post-operative evaluation

NSR before trial without stimulation was at a maximum of 10 out of 10. After placement of the Freedom stimulator at trial the maximum NSR was 3. At three-month follow-up, subject reported to be completely pain free while applying stimulation. The patient continued to take the following medications: Pregabalin 1 x 150 mg and oxycodone plus naloxone 10/5 mg as needed for pain on the left side where the subject had the same problem. No adverse events were reported.

Discussion

Wireless PNS is an option for chronic, refractory pain as it can yield effective pain control in a limited target area [9,15]. SCS and PNS use with off-label SCS device components can lead to technical shortcomings, such as device alignment, stimulation parameters, and implant-related complications like lead migration, fracture, and malpositioning. Additionally, they may not cover the entire area of pain distribution. The Freedom stimulator, a novel minimally invasive wireless device, alleviates the complications of conventional devices with PNS, which are too long and heavy, causing possible deformations of the electrodes.

The success of the wireless PNS may be accounted for by the activation of intradermal receptors and neuronal contacts along physiological anterograde conduction. The device does not recruit motor fibers and therefore does not cause any tetanic spasms of the muscles [9].

The modality's effectiveness was reported in the Austrian retrospective study of a large group of 111 Austrian patients. The conductors of the study saw a significant reduction in the mean pain intensity and reduction in pain medication. Notwithstanding, lead dislocation occurred in 13%, lead fractures in 5%, and infection in 6% of cases.

In addition, PNS is useful as an adjunctive therapy with SCS for patients with persistent back pain and failed back surgery syndrome (FBSS), providing good pain relief [7-9].

Implanted pulse generators (IPG) can also cause problems. Hamm-Faber et al. revealed IPG problems in 27% (3/11) cases, and repositioning of the IPG as a result of pain caused by tilting of the battery in 27% (3/11). The team also reported a connector problem between the lead and the extension cable in one patient (9%) [16]. Moreover, in a series reported by Buiten et al., IGP-related complications were noted in 3/7 cases (42%) where conventional PNS implant systems were used for control of refractory angina

[17]. We can deduce that complications such as pain related to the shape and bulk of IPGs are common and significant. In a two-year study that was recently completed, high frequency (HF) 10 kHz SCS had incidence of implant site pain (12.9%) and lead migration requiring surgical revision (3%) not unlike the traditional SCS (13.4% and 5.2%, respectively) [18]. For those patients with the conventional devices used for PNS, high-energy consumption was also reported to be an essential concern [16].

Meralgia Paresthetica is a difficult condition to control. In our case, we show the analgesic effect of wireless neuromodulation. We stress that this technique is completely devoid of IPG complications. Noteworthy is the fact that the conventional implant devices have genuine limitations as a result of lead-related and battery-related adverse events. The wireless PNS system requires only a small incision to place the electrode. Further incisions or implants are not required during the entire treatment procedure.

Because of the lack of an IPG as an additional anchor with the wireless PNS procedure, the possibility to observe serious lead dislocation is present. However, the occurrence rate is considered to be very low. In this case, and in recent studies, tines were added to the leads to reduce the risk of migratory leads.

The nature of this technology is minimally invasive and thus is offering inimitable help to patients with:

- Compromised immunity
- Retro-viral infections
- Co-morbid conditions such as Diabetes mellitus
- Limited life expectancy in painful conditions associated with malignancy

The main limitation of wireless peripheral nerve field stimulation is the lack of larger patient population and randomized-control groups to establish its efficacy and the potential advantage it has over the available neuromodulation technology.

Nonetheless, because of its simplicity, low adverse events, and cosmetic acceptability compared to present day systems, the above reported minimally invasive wireless technology offers an inviting treatment option for comparable pain relief [19].

References

1. Clark JD. Chronic pain prevalence and analgesic prescribing in a general medical population. *J Pain Symptom Manage.* 2002; 23: 131-137.
2. Mantyselka P, Kumpusato E, Ahonen R, et al. Pain as a reason to visit the doctor: a study in Finnish primary health care. *Pain.* 2001; 89: 175-180.
3. Barolat G. A prospective multicenter study to assess the efficacy of spinal cord stimulation utilizing a multi-channel radiofrequency system for the treatment of intractable low back pain and lower extremity pain. Initial considerations and methodology. *Neuromodulation.* 1999; 2: 1179-1183.
4. Tamimi MA, Davids HR, Langston MM, et al. Successful treatment of chronic neuropathic pain with subcutaneous

- peripheral nerve stimulation: four case reports. *Neuromodulation*. 2009; 12: 210-214.
5. Mironer YE, Hodge PJ, Parrot JT, et al. A unique approach to neurostimulation in patients with previous two-segment spine surgery and obstruction of epidural access for spinal cord stimulation: a case series. *Neuromodulation*. 2012; 15: 204-209.
 6. Sator-Katzenschlager S, Fiala K, Kress HG, et al. Subcutaneous target stimulation (STS) in chronic non-cancer pain: a nationwide retrospective study. *Pain Pract*. 2010; 10: 279-286.
 7. Pacius PM, Bernstein CA, Lempert-Cohen C. Peripheral nerve field stimulation in chronic abdominal pain. *Pain Physician*. 2006; 9: 261-266.
 8. Goroszeniuk T, Kothari S, Hamann W. Subcutaneous neuromodulating implant targeted at the site of pain. *Reg Anesth Pain Med*. 2006; 31: 168-171.
 9. Monti E. Peripheral nerve stimulation: a percutaneous minimally invasive approach. *Neuromodulation*. 2004; 7: 193-196.
 10. Barolat G. Subcutaneous peripheral nerve field stimulation for intractable pain. In: Krames E, Peckham PH, Rezai A, eds. *Neuromodulation*. San Diego, CA: Elsevier. 2009: 1017-1020.
 11. Reverberi C, Bonezzi C, Demartini L. Peripheral subcutaneous neurostimulation in the management of neuropathic pain: five case reports. *Neuromodulation*. 2009; 12: 146-155.
 12. Kim D, Vakharyia R, Kroll HR, et al. Rates of lead migration and stimulation loss in spinal cord stimulation: a retrospective comparison of laminotomy versus percutaneous implantation. *Pain Physician*. 2011; 14: 513-524.
 13. Holsheimer J, Khan YN, Raza SS, et al. Effects of electrode positioning on perception threshold and paresthesia coverage in spinal cord stimulation. *Neuromodulation*. 2007; 10: 34-41.
 14. Eldabe S, Buchser E, Duarte R. Complications of spinal cord stimulation and peripheral nerve stimulation techniques: A review of the literature. *Pain Med*. 2016; 17: 325-336.
 15. Lawrence WS Jr, Grant TR, Nancy EC, et al. Peripheral subcutaneous electrostimulation for control of intractable post-operative inguinal pain: a case report. *Neuromodulation*. 2001; 4: 99-104.
 16. Hamm-Faber TE, Aukes H, Van Corp E-J, et al. Subcutaneous stimulation as an additional therapy to spinal cord stimulation for the treatment of low back pain and leg pain in Failed Back Surgery Syndrome: four-year follow-up. *Neuromodulation*. 2015; 18: 618-622.
 17. Buiten MS, DeJongst MJL, Beese U, et al. Subcutaneous electrical nerve stimulation: a feasible and new method for the treatment of patients with refractory angina. *Neuromodulation*. 2011; 14: 258-265.
 18. Kapural L, Yu C, Doust MW, et al. Comparison of 10 kHz high frequency and traditional low frequency spinal cord stimulation for the treatment of chronic pain and leg pain: 24-month results from a multicenter, randomized, controlled pivotal trial. *Neurosurgery*. 2016; 79: 667-677.
 19. Yearwood TL, Perryman LT. Peripheral neurostimulation with microsize wireless stimulator. *Prog Neurol Surg*. 2015; 29: 168-191.